

# Research Journal of Pharmaceutical, Biological and Chemical Sciences

## Rendu-Osler-Weber disease. Case report.

S. V. Kurochkin<sup>1\*</sup>, I. R. Chuvashae<sup>2</sup>, D. I. Zidikhanov<sup>1</sup>, and M. S. Gafurov<sup>2</sup>

<sup>1</sup>Radiology Department of Hospital at Federal Autonomous Educational Establishment for Higher Education (FAEEHE) 'Kazan Federal University', city of Kazan, the Republic of Tatarstan, Russia.

<sup>2</sup>Department of Magnetic-resonance Imaging, 420043, city of Kazan, the Republic of Tatarstan, Russia

### ABSTRACT

Rendu-Osler-Weber disease is the most frequently observed genetic hemorrhagic angiopathy with local wall thinning, distention of microcirculation vessels' lumen, and incomplete local hemostasis. This pathology is inherited per autosomal-dominant type with a various pathologic gene's frequency of occurrence. As per the literature, the frequency of occurrence of this anomaly equals 1:100 000, although as of today, according to the newest studies, it is possible that the number of this nosology's events would increase up to 1:5000-8000. According to the modern ideas, Rendu-Osler-Weber disease is an example of vascular pathology (with the distress of anatomical continuity of vessels) with a congenital tendency to malformation of blood vessels (vascular dysplasia). This anomaly is characterized by the inadequacy of mesenchyme. The anatomical substrate of the disease of represented by thinning of the vessel wall with the lack of elastic and muscular layers. That's why the wall is represented by the endothelium solely, surrounded by the loose connective tissue. Because of this, arteriovenous aneurysms appear, which cause hemorrhages due to the vulnerability of vessel walls.

**Keywords:** Rendu-Osler-Weber disease, vascular pathology, vessel wall.

*\*Corresponding author*

## INTRODUCTION

In the majority of the patients, telangiectasia first appear on lips, wings of the nose, on the cheeks, above the eyebrows, on the tongue, gums, nasal mucosa (at rhinoscopy they are hardly discovered even if bleedings take place). Then they may appear in any skin area, including hairy part of the head and the tips of the fingers. In most cases, hemorrhagic events start with nasal hemorrhages, which are very often prone to exacerbation. Sometimes only one nasal passage is bleeding for a long time, and sometimes the bleedings are interchanged in various locations.

The intensity and duration of bleedings may vary greatly – starting from relatively scant and not so long-lasting, and ending with extremely persistent and lasting almost without interruptions during many days and weeks, leading to extreme anematization of patients [1,2,3].

The study of the system of homeostasis doesn't detect any significant abnormalities that can cause hemorrhages. Only secondary reactive changes are possible, which are conditioned by the blood loss (moderate hyper coagulation, thrombocytosis), anemia [3] or, vice versa, polyglobulia at arteriovenous shunt. At the same time, at the presence of multiple telangiectasias, the occurrence of the symptoms of inopia (consumption coagulopathy) with thrombocytopenia are possible to occur [2].

In most cases, the disease is morphologically conditioned by the presence of multiple telangiectasias that are settled on skin, mucous membrane of tongue, nose, bronchi and gastro-intestinal tract.

According to the literature [3-5], such telangiectasias represent pathologic capillary fistulas between arterioles and veinlets, which settle on skin and mucous membranes (most often – nasal cavity membrane and is manifested in the form of bleedings), and also in parenchyma of the visceral organs (liver, cerebrum) in the form of malformations.

As exemplified by the presented clinical case, the possibilities of various methods of radio diagnostics in detection of changes on the part of parenchymatous organs in patients with hereditary hemorrhagic telangiectasia are presented for your attention.

**The clinical case.** Male patient, 56 years old, was admitted to Autonomous public health care institution 'Republican Clinical Hospital' No. 2 (currently named as Hospital at Federal Autonomous Educational Establishment for Higher Education 'K(P)FU') with the aim of performing a follow-up examination concerning updates on changes in liver, that had been detected before during planned ultrasound examination.

Complaints: of periodic nasal bleedings, angiostraxia, the presence of unpainful 'nodules' on the oral mucosa, skin of fingers and nose.

Anamnesis: the above-mentioned complaints first appeared about 8 years ago, when the patient noticed the appearance of spontaneous nasal hemorrhages and the occurrence of 'the nodules'. Later the complaints were growing in frequency and intensity. During the last 6 months, the patient noticed the occurrence of nasal hemorrhages that occur at postural change.

Hereditary background:

1. The paternal grandfather, born 1896, noticed some episodes of nasal bleedings, and later he suffered from anemia. He died at the age of 80. The death was caused by pulmonary heart disease.
2. Father, born 1925, suffered from high blood pressure; in 2004 suffered an acute cerebrovascular accident of hemorrhagic type and died of complications of intracerebral bleeding.
3. Blood brother, born 1956 – no episodes of nasal bleedings as of the moment of clinical study's composition were detected.

At physical examination, some single small thick nodules (in the sort of telangiectasias) were detected: submucosal ones on the inferior surface of the tongue (Figure 1), and the lower lip (Figure 2).

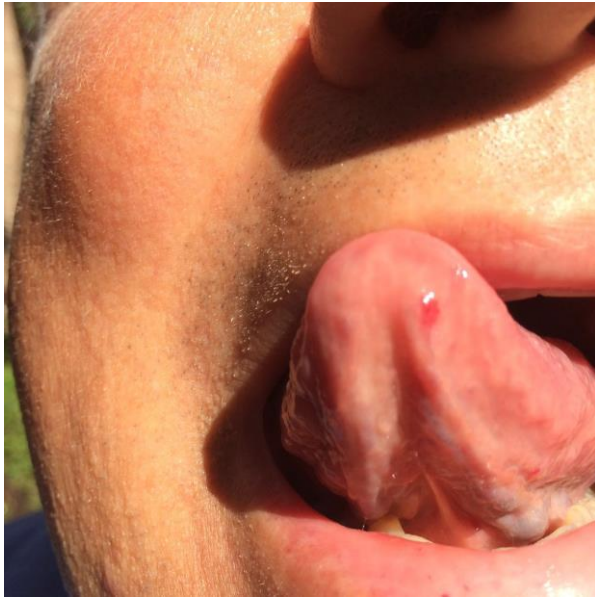

Figure 1

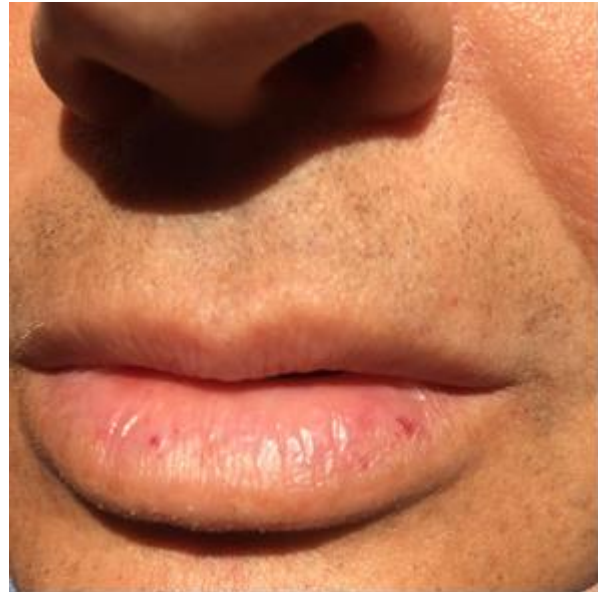

Figure 2

On an outpatient basis, the patient had the **ultrasonic examination of abdominal cavity organs and retroperitoneal space** undertaken:

The liver is at the edge of the costal arch. The contour is abrupt. The structure is inhomogeneous, in S6 a palpable dominant abnormality with a diameter of 21 mm is observed. The gall bladder's dimensions are 97x37 mm. In the cervix, there is a concrement with a diameter 7 mm. The walls are not thickened. The choledochous duct has a size of 5 mm. Extrahepatic bile ducts are not dilated. The pancreas is diffusely enlarged, 37-19-25 mm. The structure is deprived of the obvious local pathology. Para-aortic lymph nodes are not determined. The right kidney's dimensions are 112x51 mm. The parenchyma is 17 mm. The contours are even. The renal collecting system is indurated and not dilated. The left kidney's dimensions are 117x57 mm. The parenchyma is 19 mm. The renal collecting system is indurated and not dilated. In the projection of the adrenals, no evident local pathology is detected. In pleural cavity, no fluid collection is detected.

**Pelvic ultrasound examination (by transabdominal access):** urinary bladder:  $V = 35 \text{ cm}^3$ . There are no evident mural formations. The content is homogeneous. Prostate's dimensions are 40x47x48 mm. The contours are uneven. On the anterior surface, there is an adenomatous nodule with  $d=32 \text{ mm}$ .

With the purpose of clarification of the character of liver's focal change that was detected by means of ultrasound examination, the patient had the dynamic contrast-enhanced magnetic resonance imaging taken, as well as the computed tomography angiography of abdominal cavity organs and retroperitoneal space.

**The dynamic contrast-enhanced magnetic resonance imaging of the upper abdomen and retroperitoneal space ("Omniscan", 20 ml).**

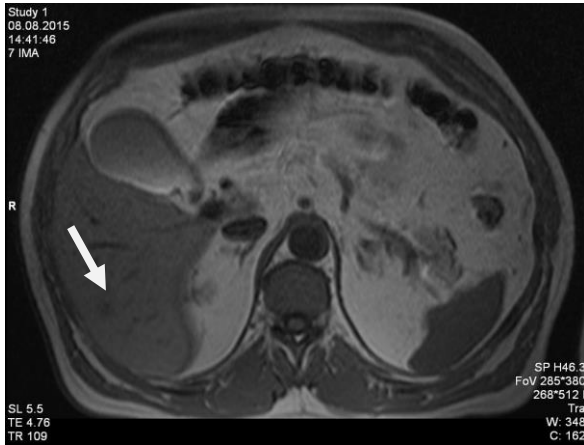
The examination was performed with the help of SIEMENS» MAGNETOM SYMPHONY apparatus, 1.5 T.

At MR images, the axial, front and sagittal projections were obtained with the reference to the upper abdomen and retroperitoneal space in T1- and T2-weighted images (WI).

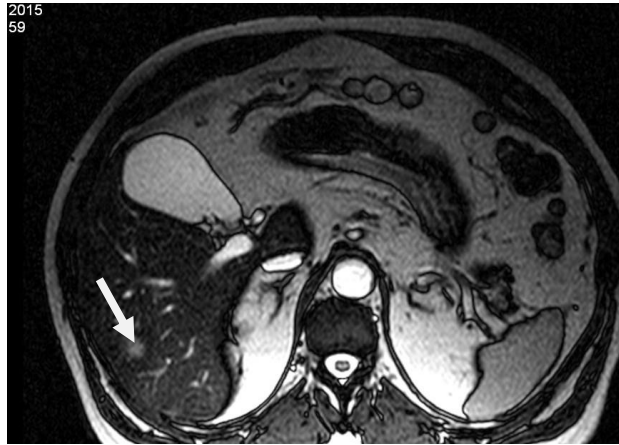The liver is not enlarged, in SVI a homogeneous, slightly hypointense in T1-wi and insignificantly hyperintense in T2-WI, with rather distinct borders, formation with the sizes of up to 15-17 mm (Figures 3 a,b, 4a); the structure in other segments is homogeneous, without local pathology; the enlargement of the biliary tract and intrahepatic vessels were not detected. The gall bladder is of a normal size, it is not deformed, the

content is homogeneous (liquid), and the walls are not thickened. The pancreas is not enlarged, the contours are even, it is not deformed, and no local pathology is observed. Wirsung's duct is not visualized. The lien is of a usual form and position, it is not enlarged, and no local pathology is observed. Hyperplasia of retroperitoneal space's lymph-node is not observed.

At dynamic contrast enhancement ('Omniskan', 20 ml) – a quick homogeneous contrasting with a long-time retention of contrast agent in the projection of the formation (Figure 5).



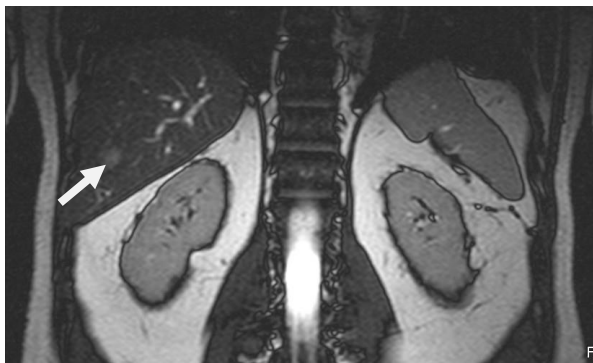
a) MR image, axial projection of T1-WI



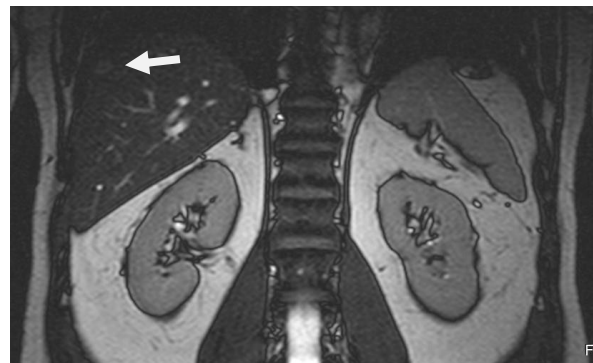
b) MR image, axial projection of T2-WI

Angioma of liver in S6

Figure 3



a) Angioma of liver in S6



b) Angioma of liver in S7.

MR images, the frontal projection, T2-WI

Figure 4

At MR images that were received in the frontal projection T2-WI – in S7 subcapsular, a slightly hyperintense formation with quite clear borders is hardly differentiated. The formation is similar to the one present in S6 (Figure 4b).

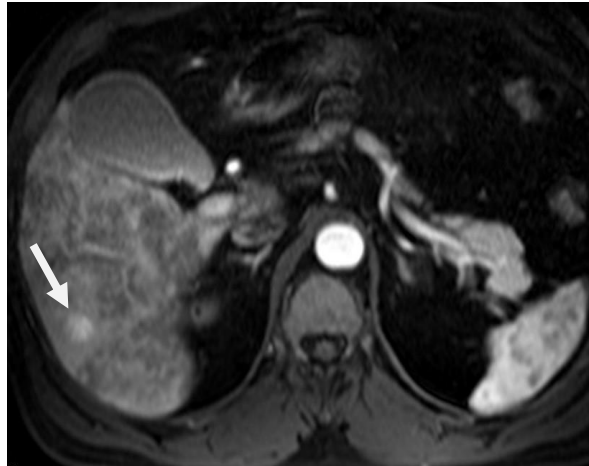


Figure 5

**T1-WI (after contrast enhancement). Angioma in liver in S6**

**Conclusion.** Local focal abnormalities in SS VI, VII in liver (considering the character of contrasting of the focus SVI, angioma of the liver is more probable). If there is a necessity to the detailing of the changes' character, a dynamic follow-up, a puncture biopsy and ultrasound follow-up with morphological verification of biopsy material should be performed.

**Computed tomography angiography (CTA) of abdominal cavity organs and retroperitoneal space**

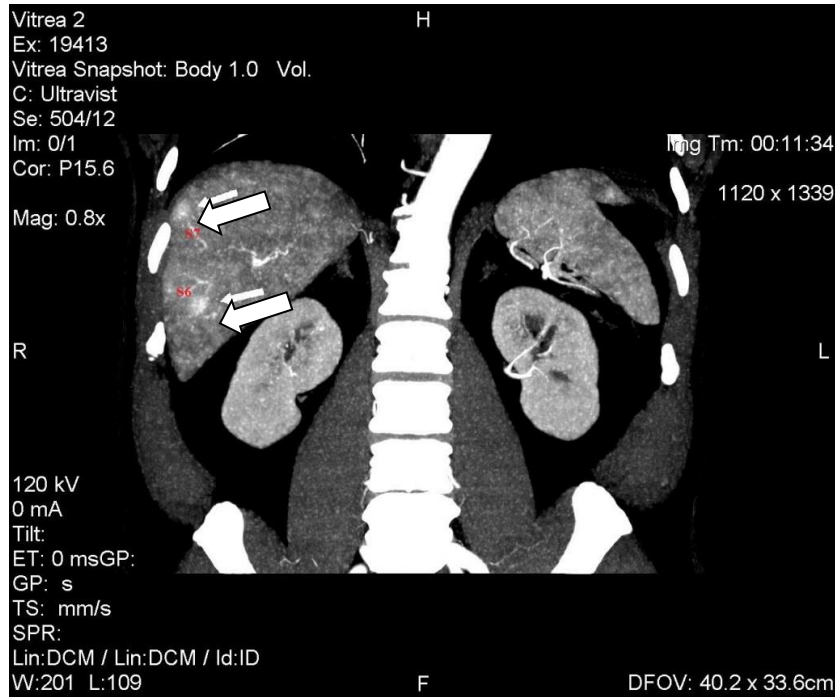
The examination was performed with the help of Aquilion 64 (Toshiba) apparatus. Examination record: a typical patient positioning for examination of the region of interest ("feetfirst", "supine"); a topogram (at the breath holding); native scanning (at the breath holding); section thickness - 5.0 mm with further 3D imaging with a section thickness of 0.5 mm; rotation time of the tube is 0.5 s; CTA in the "abdomen" mode; trigger on the level of descending part of aorta, the density is 150 Hu; scanning latency time is 5 s, the administration rate of the contrast medium is 4 cm/s. The contrast medium: Iopromidum (Ultravist), concentration of iodine – 370 mg/ml, the volume = 100 ml. The administration was bolus, through perfusion catheter G18, fixed into the cubital vein, with the application of the double-headed injector OptiVantage, which was synchronized with the tomographic scanner. Radiation exposure: 50.8 mGy. No adverse reactions were observe.

The protocols of description No. 5608, No. 5609.

Liver. The borders are even, the parenchyma's density is diffusely reduced. Hyperplasia of the left lobe of liver reaches the splenic angle.

At CTA in arterial phase in SVI, an intense focal, up to 1.3 cm, and less intense subcapsularly in SVII (up to 1.5x0.7 cm) contrast uptake with its time latency (Figure 6).



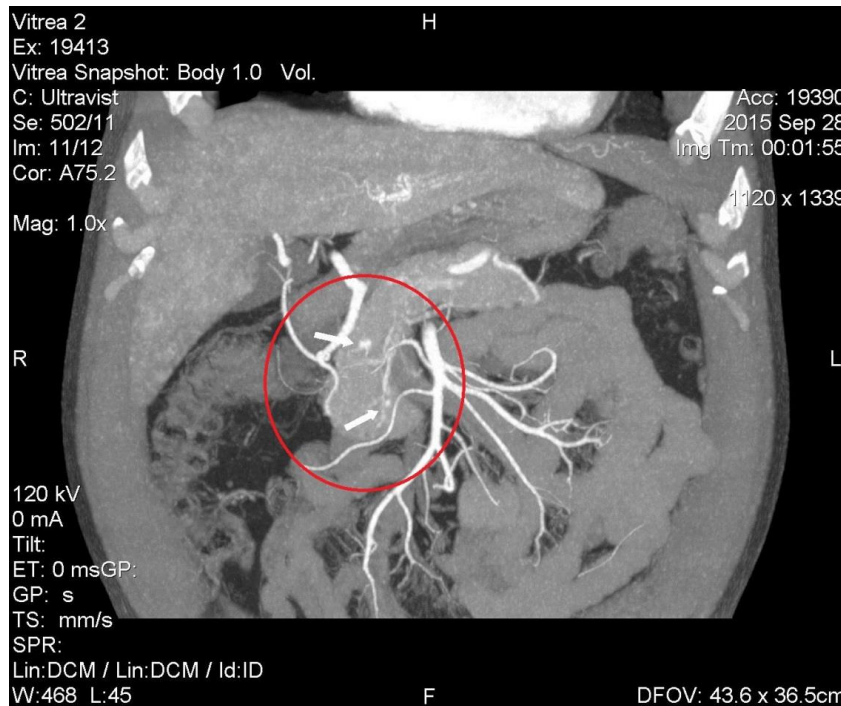


**Figure 6**

**MIP -reconstruction, frontal view, early arterial phase. Angiomas in the liver in SS VI,VII.**

The gall bladder is of standard form and size, its walls are not thickened, the content is deprived of radiopaque stones. Extrahepatic bile ducts are not dilated. The choledochal duct is not dilated.

The pancreas is not enlarged, it is lobulated, the density of parenchyma is not changed, the structure is deprived of visible focal changes. At CTA, in the early arterial phase, an intense focal and intense contrast uptake in the head (No. 2 up to 0.8x0.5 and 0.5 cm) and in the tail (No. 2 up to 0.7 и 0.6 cm) (Figures 7-12), which is similar to accumulation in the liver.



**Figure 7**

**MIP-reconstruction, frontal view, early arterial phase. Angiomas of head of the pancreas**

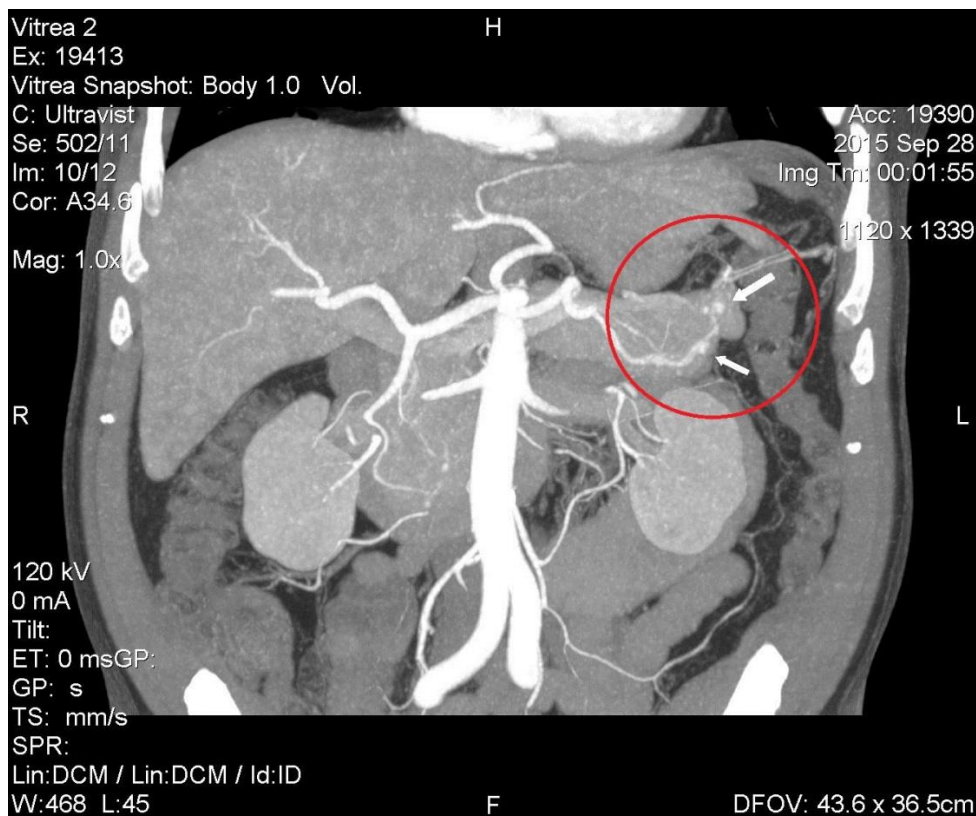


Figure 8

MIP-reconstruction, frontal view, early arterial phase. Angiomas of tail of pancreas

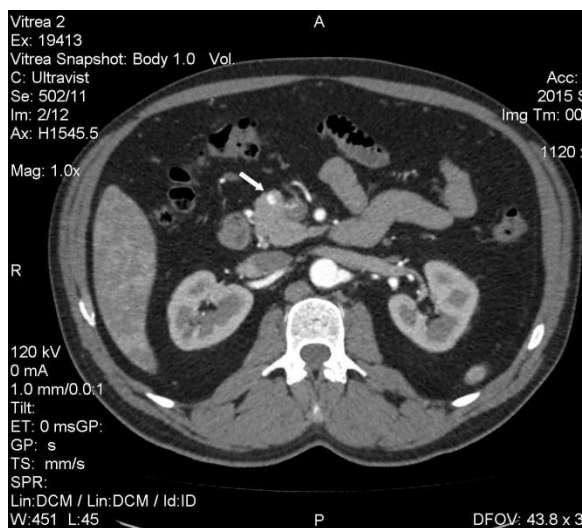


Figure 9

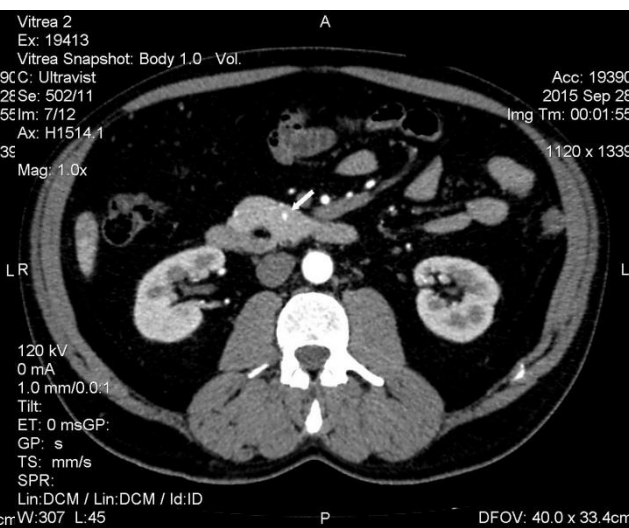


Figure 10

MIP-reconstruction, axial view, early arterial phase. Angiomas of the head of the pancreas (early arterial phase, MIP).

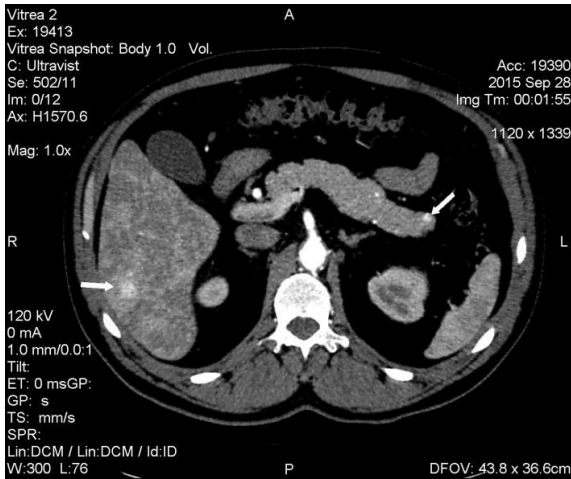


Figure 11

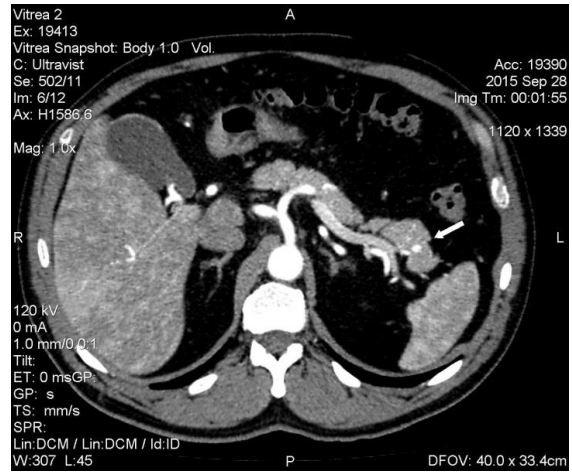


Figure 12

MIP-reconstruction, axial view, early arterial phase. Angiomas of the tail of the pancreas (early arterial phase, MIP).

On the posterior wall of the lineal artery's medium segment, there is an aneurysm with the dimensions of up to 0.9x0.8 cm with a calcified capsule (Figure 13-14).

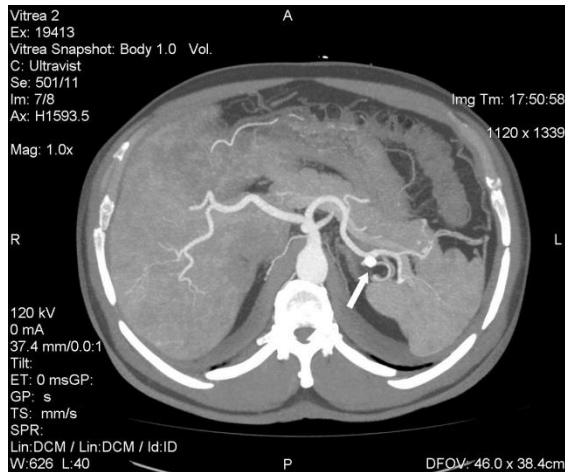


Figure 13

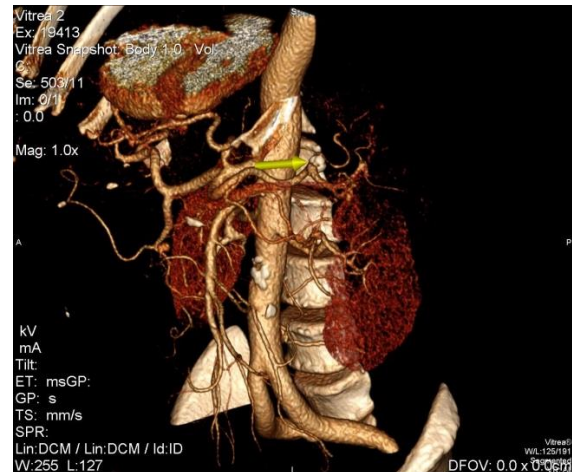


Figure 14

MIP-reconstruction, axial view, early arterial phase

3D-reconstruction, early arterial phase

The aneurysm of lienal artery.

The diverticulum of descending segment of duodenum up to 2.8x2.2x1.9 cm (Figures 15-16).

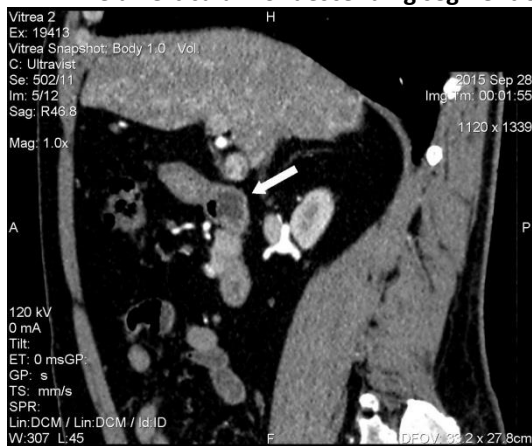

Figure 15

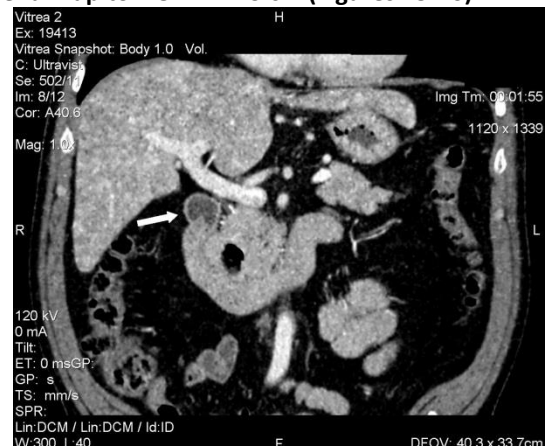

Figure 16

MIP-reconstruction, sagittal view, venous phase

MIP-reconstruction, frontal view, venous phase



The diverticulum of descending segment of the duodenum.

The lien is of normal form and size, the parenchyma's density is not changed, the structure is deprived of visible focal changes. Aorta and VCI are not dilatated. Mural calcinosis and fibrotic atheromatous plaques of the aorta with various degrees of stricture formation. Unenlarged para-aortic and mesenteric lymph nodes are visualized. There are some small diverticulums of the middle intestine.

**Conclusion.** There are some signs of angiomas SS VI,VII in the liver, head, and tail of the pancreas. Considering anamnesis and clinical implications – Rendu-Osler disease.

Diverticulum of the duodenum, diverticulosis of the middle intestine. Aneurysm of the lienal artery. Atherosclerosis of abdominal aorta.

With the purpose of detection of similar vascular formations in the cerebrum, the patient had the contrast-enhanced magnetic resonance imaging of the cerebrum taken.

**The contrast-enhanced magnetic resonance imaging of the cerebrum and non-contrast MR-angiography in 3D TOF mode.**

The examination was made with the help of «SIEMENS» MAGNETOM SYMPHONY – 1.5 T apparatus.

With the help of MR-images, made in three views, T1-, T2 WI of the cerebrum were obtained, as well as the images in FLAIR mode. No focal pathology proximal to the cerebral hemispheres, brain stem and cerebellum were detected. Midline structures are not displaced. Ventricular system is within normal limits. Extrinsic subarachnoid spaces are not changed. Convexity sulci are not enlarged. Hypophysis is of intracellar localization, the size is not changed, the glands are symmetric, the upper and lower borders are clear, even, the structure is homogeneous, the hypophysial stalk is not misplaced. There are no focal changes in the parasellar zones. The visual tracts and chiasm are or normal suite without changes in the size and structure. The eye pits are symmetric. The eye balls are of round shape, the structure of the content is homogeneous, the signal is not changed. There are no changes of anatomic structures in the retrobulbar space. The eighth cranial nerve is of normal suite on the both sides, it is not thickened, the structure is unchanged. The cerebrospinal junction is within normal limits.

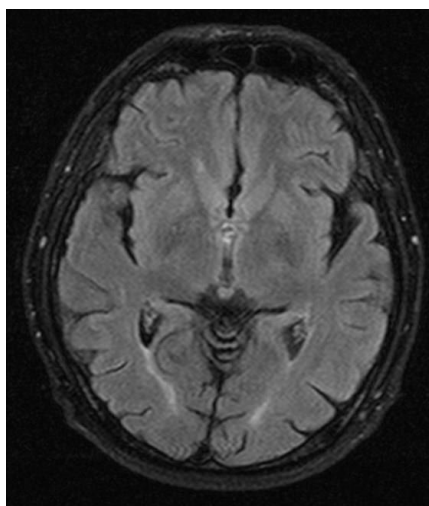


Figure 17. The image in FLAIR mode

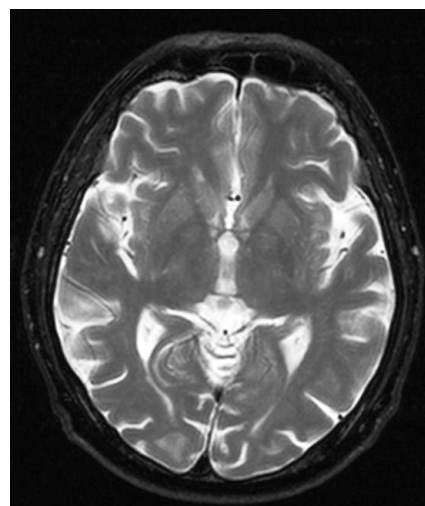


Figure 18. T2-WI

MR-images, axial projection

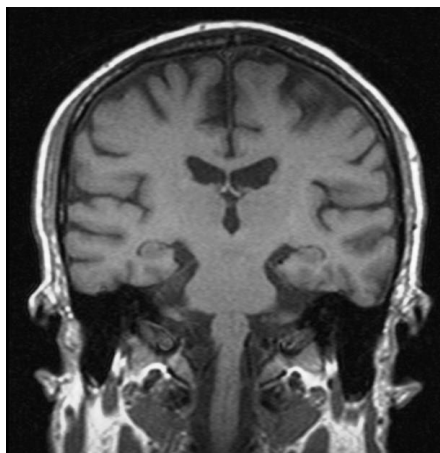


Figure 19. T1-WI

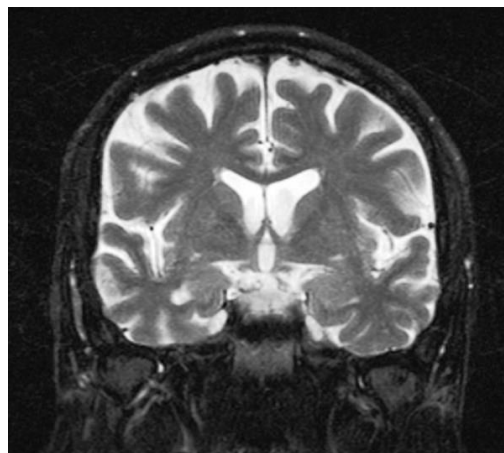


Figure 20. T2- WI

MR-images, frontal projection

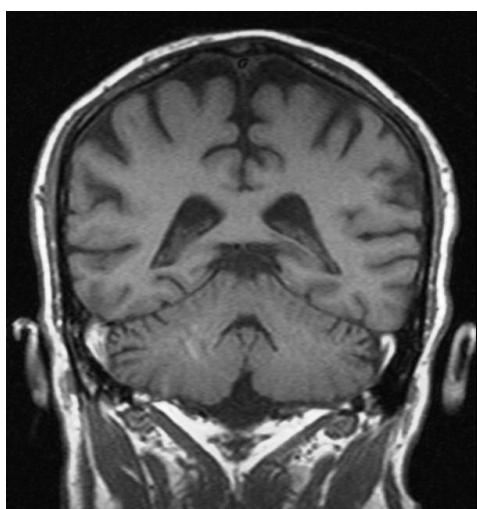


Figure 21. T1- WI

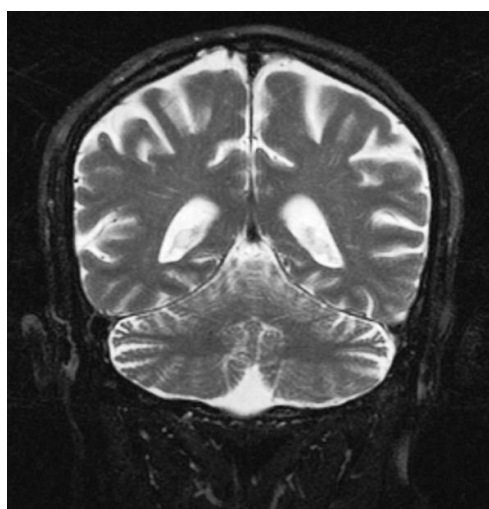


Figure 22. T2- WI

MR-images, frontal projection

At the non-contrast MR-angiograms in 3D TOF mode (Figures 23-28) no pathology was detected. The Willis's artery is not closed.

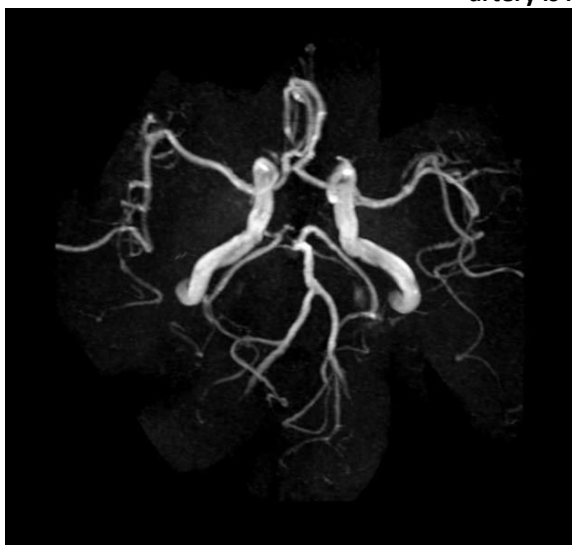

Figure 23. The bottom view

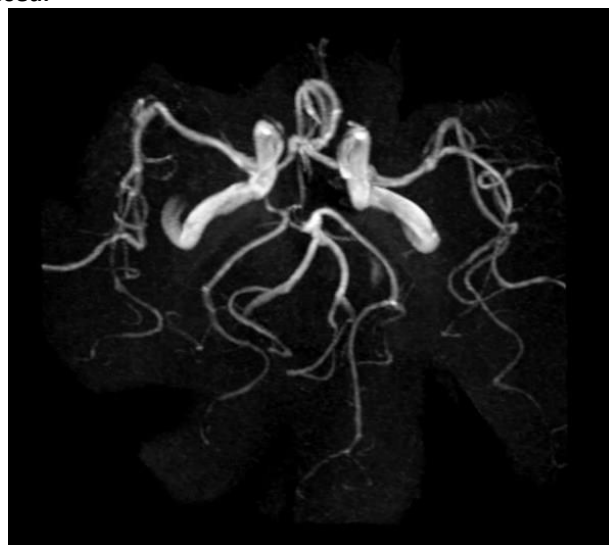


Figure 24. The top view

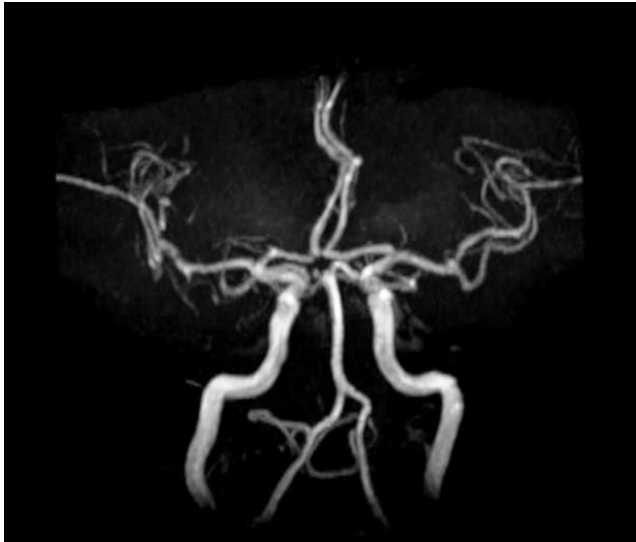

Figure 25. The back view

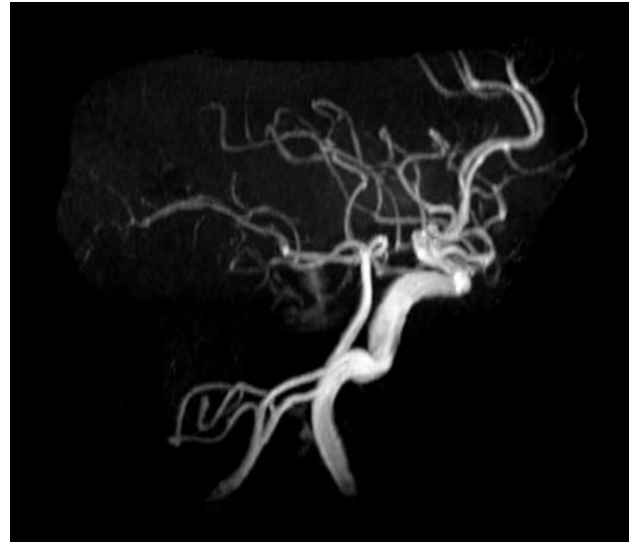

Figure 26. The right view

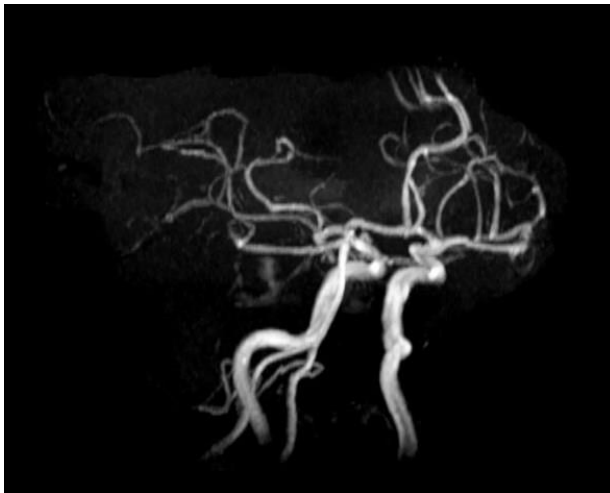

Figure 27. The right view (with rotation of ½)

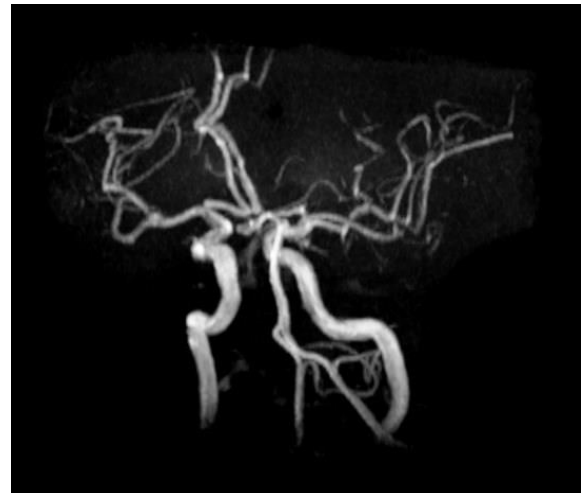

Figure 28. The left view (with rotation of ½)

**Conclusion:** the signs of expansive process (t-r) and local pathology of the cerebrum were not detected.

### DISCUSSION

Genetic hemorrhagic telangiectasia or Rendu-Osler-Weber disease was first-ever described by Sutton in 1864 and Benjamin Guy Babington in 1865 as a genetic nasal hemorrhage. In 1896, Wile Henry Randu defined this disease as a pseudo hemophilia, which is manifested by genetic nasal bleeding. In 1901, William Osler described clinical symptoms and defined their genetic character, Frederick Parks Weber (1907) considered Rendu-Osler-Weber disease a separate nosologic unit, different from genetic hemophilia; and Heins (1909) defined the syndrome as genetic hemorrhagic telangiectasia [5].

According to the data presented in the foreign literature, Rendu-Osler-Weber disease is manifested in two forms, each of which is conditioned by the pathology of particular genes: at this, the first type is manifested through involvement of cerebral blood vessels into the pathological process, while the second one – by mainly involvement of liver parenchyma, just like it is in the case, presented by us [3,4]. The key point is that in any case a certain gene is damaged – the gene that produces proteins that are necessary for the formation of vessels' walls, which is the reason of occurrence of specific pathologically changed vascular areas [6].

In the classical description, provided by William Osle, three types of telangiectasias are distinguished: a) the early one – telangiectasias in the form of small, irregularly shaped “spots”; b) the intermediate one – in

the form of vascular “spiders”; c) nodule type – in the form of bright red round or oval nodules with a diameter of 5-7 mm that project above the skin surface or mucous membrane for 1-3 cm. In patients who are more than 25 years old, often telangiectasias of two or even three types at a time are found. All of them differ from other formations because they become pale when being pressed, and are filled with blood after the tension is stopped [1,5]. In our case, the patient had single nodules that projected above the skin surface of the palms and the mucosal membrane of the oral cavity with a diameter of up to 0.5 cm, which corresponded to manifestations of Rendu-Osler-Weber disease; similar changes are described in the literature [2-4].

Rendu-Osler-Weber disease is a rare vascular pathology with a genetic origin and the absence of a typical pathognomonic clinical picture. The main purpose of radiological methods of investigation is the detection of pathologically changed vascular areas in the organs and tissues.

It should be noted that in order to establish diagnosis, one should operate the criteria, offered by Curacao [2-10], which were adopted by Scientific Advisory Board of the International community of genetic hemorrhagic telangiectasia in 1999, and which state the following:

- Spontaneously occurring and discontinuing nasal bleedings.
- Multiple telangiectasias, including the ones with a distinctive localization (lips, oral pharynx, fingers, and nose).
- Visceral injuries – arteriovenous malformations of gastrointestinal, pulmonary, hepatic or cerebrospinal localization.
- Family anamnesis – the presence of genetic hemorrhagic telangiectasias in the close relatives.

The credibility of the presence of the disease is defined by the combination of the abovementioned criteria and is estimated in the following way:

Certainly – in case of the presence of three and more criteria

Possibly – in case of the presence of two criteria

Unlikely – in case of the presence of fewer than two criteria

In our case, we dealt with the absolute index of meeting the Curacao criteria and credibility.

At the same time, it is necessary to emphasize that the detected angiomas in the liver, head, and tail of the pancreas were incidental findings. In our monitoring, on the base of performed examinations (CTA, MRT and CT angiography of abdominal cavity organs and retroperitoneal space), the character of detected focal changes was assessed, as well as the differential diagnostics, which was made after the examinations. As distinct from MRT and CT angiography, during the performance of CTA, it was possible to detect and characterize additional focal changes not only in the liver, but also in the pancreas, i.e., the foci of vascular dysplasia of untypical localization for this pathology.

The value of the method of reliable and quality assessment of detected foci lies in the application of four-phase CT with the discretion of the four successive stages of contrast enhancement – the early one, the later arterial one, portal one and excretory one. In regard to MRT, here in spite of dynamic enhancement, it was possible to detect and assess angioma SVI in liver, proved with relation to MR.

In this clinical observation, the detection of small angiomas, which are typical, among others, to vascular pathologies and genetic hemorrhagic telangiectasias in particular, vividly demonstrates the unique possibilities for CTA, making the method a highly informative one for diagnosing vascular pathologies.

According to the literature [10], the application of MRT is the most relevant step for assessment of the disease and the presence of vascular cerebral affections, which are typical for this disease. In our observation, as per the results of target MRT of the cerebrum and non-contrast MR-angiography, which was performed in order to assess the condition of parenchyma and cerebral arteries, no pathologies from the side of parenchyma and cerebral arteries were detected.



## SUMMARY

Basing on the literature data and on our clinical observation, it is evident that Rendu-Osler-Weber disease is a rare vascular pathology, which of congenital nature, but which doesn't have any specific clinical picture, and is accompanied with morphological changes in the visceral organs. Thus, we believe that: a) patients with this disease should obligatory have CTA taken with the purpose of obtaining necessary additional information about the presence of typical changes from the side of parenchymal organs and selection of the tactics of patients' case management; b) CTA is a procedure with ample diagnostic opportunities, which is highly competitive with invasive methods, and must be used as a method of choice for examination of patients with atypical vascular pathology.

## ACKNOWLEDGEMENTS

The work is performed using the funds of the aid, granted as a part of the government support, provided to Kazan (Privolzhye) Federal University with the purpose of boosting its competitiveness among the global leading research and education centers.

## REFERENCES

- [1] Drozdova M.V. Blood disorders - 2009.
- [2] Vesna Šupak, Lidija Bilić-Zulle, Antica Duletić-Načinović, Elizabeta Fišić. A case report of hereditary hemorrhagic telangiectasia with severe anemia. // *Biochemia Medica* — 2008; Vol. 18 (2): 106-114.
- [3] D.Venkateswara Raju, A.Sai Chandra niveditha, Dr. B. Lakshmi Prasad, Dr. A. Aswini Kumar, Dr. Swarnalatha G. Hereditary hemorrhagic telangiectasia - a rare cause of severe iron deficiency anemia. // *Indian journal of applied research*. — July 2014. — Vol.4 (7).
- [4] Paulo Sérgio da Silva Santos; Karin Sá Fernandes; Marina Helena Magalães. Osler-Weber-Rendu syndrome — dental implications. // *Journal of the Canadian Dental Association*. — September 2009. — Vol. 75 (7).
- [5] A. A. Sharathkumar A., Shapiro. Hereditary hemorrhagic telangiectasia. // *Haemophilia journal*. — 2008. — Vol.14. P: 1269-1280.
- [6] Antônio José Cortez Juares, Alfredo Rafael, Dell'Aringa, José Carlos Nardi, Kazue Kobari, Vera Lúcia Muller Gradim Moron Rodrigues, Renato Martins Perches Filho. Rendu-Osler-Weber Syndrome: case report and literature review // *Revista Brasileira de Otorrinolaringologia* — 2008. — 74(3): P452-457.
- [7] Dr. Sanjay Joshi, Dr. Vineet Kulakarni. A Case Report of Osler-Weber-Rendu Syndrome // *Journal of dental and medical sciences* — June 2015. — Volume 14, Issue 6 Ver. IV.
- [8] Junghoon Ha, Byoung Kwan Son, Sang Bong Ahn, Young Kwan Jo, Seong Hwan Kim, Yun Ju Jo, Young Sook Park and Yoon Young Jung. Osler-Weber-Rendu disease presenting as recurrent portosystemic encephalopathy in a 75-year-old female patient // *The Korean Journal of Gastroenterology* — 2015 — Vol. 65 (1): P57-61
- [9] B. Della Vella, V. Unfer, C. Nania, M.L. Borgia, A. Saraceno, M. Minozzi. Hereditary haemorrhagic telangiectasia and pregnancy: a case report. // *European Review for Medical and Pharmacological Sciences*. — Vol.16 (7): P986-989.
- [10] Vladimir Vukomanović, Milovan Matović, Vesna Ignjatović, Branislav Belić. Rendu-Osler-Weber syndrome: a case report. // *Macedonian Journal of Medical Sciences* — December 2014 — Vol. 2(4): P613-617.